

LETTER TO THE EDITOR

A New Atlanto-Occipital (C0-C1) Joint Injection Technique

Dear Editor,

Some patients with chronic neck pain also suffer from occipital headache. They can also be disabled by dizziness, nausea, vomiting, anxiety, fatigue, insomnia, and balance difficulty [1–3]. In normal volunteers, pain from the atlanto-occipital (AO) joints can be referred to the neck and to the occipital region [4]. Therefore, the differential diagnosis of occipital pain should include the AO joints. AO joint blocks provide an objective means for diagnosing this source of pain [4–6].

A posterior approach for AO joint blocks has been detailed [7], but theoretically it is subject to hazards. The third part of the vertebral artery emerges from the foramen transversarium of C1 to pass medially behind the lateral mass of the atlas. In this region, the course of the vertebral artery is variable and may be tortuous [8], putting it at risk of penetration by needles inserted along a posterior approach. For fear of catastrophic consequences from such penetration, many interventional spine specialists have abandoned performing upper cervical injections [9,10]. We describe here an alternative posterior approach for AO joint blocks that may help to alleviate some of the safety concerns associated with the traditional injection method.

The patient is placed in the prone position with a wedge or pillow placed under the sternum, with the head rotated to the ipsilateral side and slightly flexed. Slight head flexion widens the AO joint posteriorly and improves visualization of the posterior lateral aspect of the occipital condyle. Ipsilateral head rotation of approximately 30 degrees may displace the vertebral artery slightly to a more medial location. With the patient so positioned, the optimal trajectory to the AO joint is along an oblique view aimed at the posterolateral edge of the occipital condyle. In such a view, the superior articular process of C1 forms a cup-shaped socket, and the top edge of the cup forms a visible joint line. However, a more reliable entry point is the posterolateral aspect of the joint capsule, which is drawn upwards, above the edge of the cup, over the posterolateral edge of the occipital condyle.

Under C-arm fluoroscopy guidance with a cephalad tilt and contralateral obliquity, the occipital condyles are easily visualized. Cephalad tilt of the C-arm serves the purpose of clearing the occipital protuberance from obstructing the needle trajectory, and contralateral obliquity allows viewing of the occipital condyle clearly within the nasal. Using aseptic technique, a 25-gauge

spinal needle can be carefully advanced until the posterolateral aspect of the occipital condyle is reached (Figure 1A). Needle depth and position are assessed by obtaining a lateral view (Figure 1B). In order to confirm intra-articular access and to check for vascular injection, an arthrogram of the C0-C1 joint is obtained by injecting 0.25–0.5 mL of contrast material in the oblique view, with confirmation of intra-articular flow in the lateral view (Figure 2A and B). Digital subtraction angiography can be utilized as an additional safety measure if there is concern about intravascular injection.

This technique differs from that of Furman et al. [7], and that of Lee et al. [6], in that it adds lateral rotation to neck flexion. It resembles the technique of Dreyfuss et al. [4] but has the patient lying prone rather than in

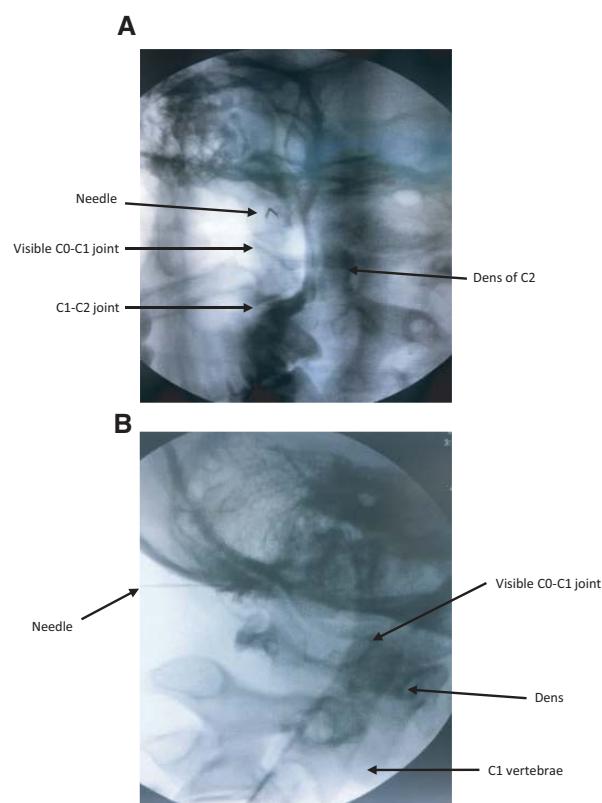


Figure 1 Fluoroscopy images of atlanto-axial joint access. (A) Contralateral oblique view with cephalad tilt showing anatomic landmarks and needle in position. (B) Lateral view showing a 25-gauge needle inserted high in the joint.

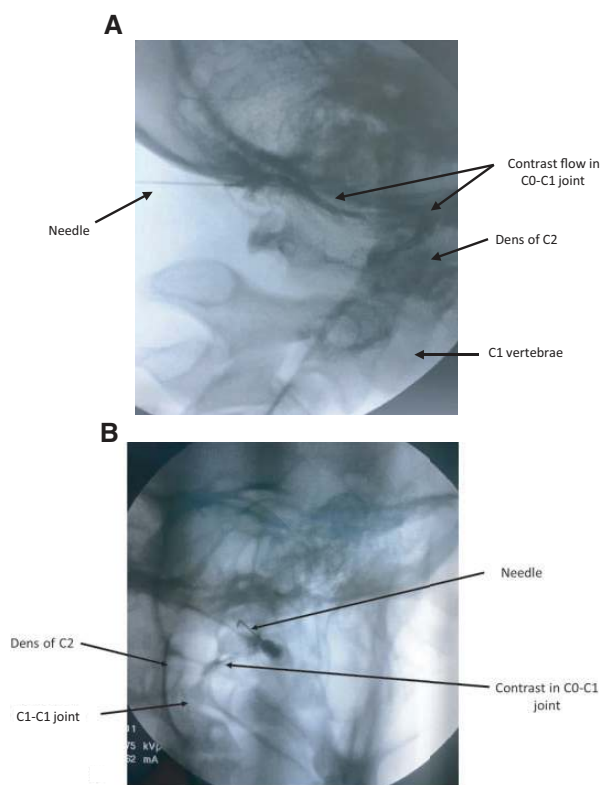


Figure 2 Fluoroscopy images of an atlanto-axial arthrogram. (A) Lateral view. (B) 30-degree oblique view.

lateral decubitus. The most significant innovations of the present technique are that lateral rotation displaces the vertebral artery medially, aiming high at the occipital condyle keeps the needle above the typical location of the vertebral artery, and aiming at the occipital condyle keeps this mass of bone between the needle and the spinal cord.

From September 2016 to January 2017, we successfully and safely completed this alternative technique in 10 patients, for a total of 20 C0-C1 joints. There have been no complications or adverse events after the procedure.

Conflicts of interest: CW, JM, and ED have declared no conflicts of interest.

Disclosure: CC is a shareholder and CMO of Regenerative Sciences, LLC, and owner of the Centeno-Schultz Clinic.

CHRISTOPHER CENTENO, MD,*[†] CHRISTOPHER J. WILLIAMS, MD,* JASON MARKLE, DO,* AND EHREN DODSON, PhD[†]
*Centeno-Schultz Clinic, Broomfield, Colorado;
[†]Regenerative Sciences, LLC, Broomfield, Colorado, USA

References

- 1 Steilen D, Hauser R, Woldin B, Sawyer S. Chronic neck pain: Making the connection between capsular ligament laxity and cervical instability. *Open Orthop J* 2014;8:326–45.
- 2 Kim HA, Yi HA, Lee CY, Lee H. Origin of isolated vertigo in rotational vertebral artery syndrome. *Neurol Sci* 2011;32:1203–7.
- 3 Sterner Y, Gerdle B. Acute and chronic whiplash disorders—a review. *J Rehabil Med* 2004;36:193–209.
- 4 Dreyfuss P, Michaelsen M, Fletcher D. Atlanto-occipital and lateral atlanto-axial joint pain patterns. *Spine* 1994;19:1125–31.
- 5 Falco FJ, Erhart S, Wargo BW, et al. Systematic review of diagnostic utility and therapeutic effectiveness of cervical facet joint interventions. *Pain Physician* 2009;12:323–44.
- 6 Lee DG, Cho YW, Jang SH, et al. Effectiveness of intra-articular steroid injection for atlanto-occipital joint pain. *Pain Med* 2015;16:1077–82.
- 7 Furman MB, Lee TS, Berkwits L. *Atlas of Image-Guided Spinal Procedures*. Philadelphia, PA: Elsevier-Saunders; 2012.
- 8 Madawi AA, Casey AT, Solanki GA, et al. Radiological and anatomical evaluation of the atlantoaxial transarticular screw fixation technique. *J Neurosurg* 1997;86:961–8.
- 9 Edlow BL, Wainger BJ, Frosch MP, et al. Posterior circulation stroke after C1-C2 intraarticular facet steroid injection: Evidence for diffuse microvascular injury. *Anesthesiology* 2010;112:1532–5.
- 10 Datta S, Manchikanti L. It is time to abandon atlanto-axial joint injections: Do no harm! *Anesthesiology* 2011;114:222–4.