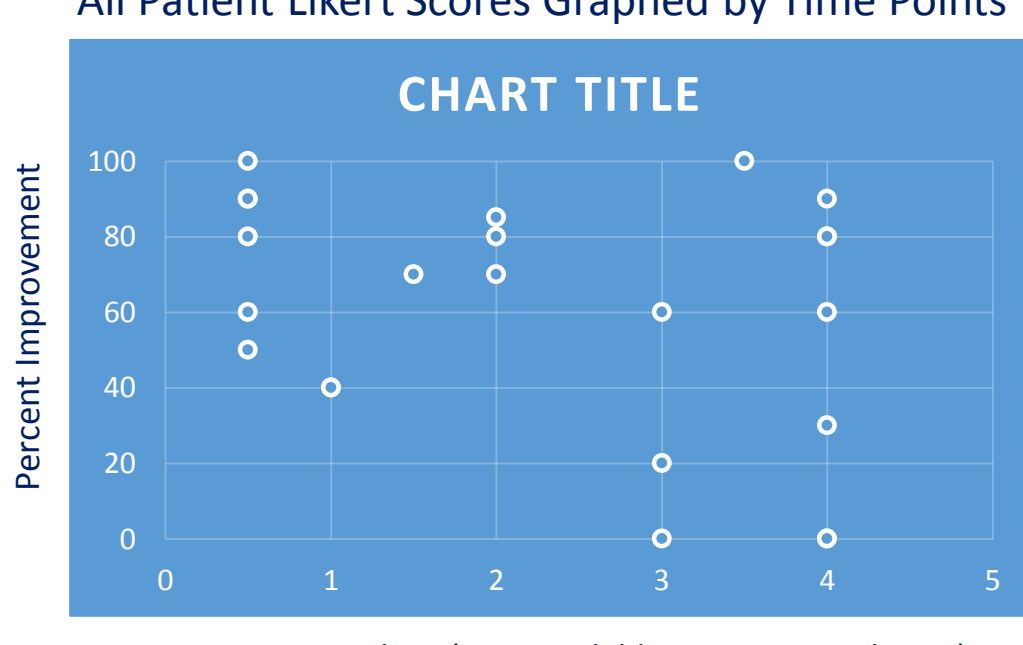


Patient Description (and applicable history)	Duration of Conventional Treatment (before disc procedure)	Treatments That Failed to Resolve Issue	Pre-Treatment Disc Status	Post-Treatment Disc Status	Reported Improvement (% Likert Change) <small>Last available report by patient and amount of time elapsed since procedure.</small>	Images
JS-42 yo male accountant who needed epidural steroid injections multiple times each year to treat radiculopathy.	6 Years	<ul style="list-style-type: none"> Narcotics Epidural Steroid Injections Physical Therapy 	Large central, contained, broadbased protrusion at L5-S1	75% Reduction in disc bulge size	70 2 Years	<p>Apr 2009-Ax T2 FRFSE ET-19, TR-5650, TE-125.2 Jan 2010-Ax T2 FRFSE ET-18, TR-5650, TE-130.0</p>
ES-24 yo female lab worker who had axial/leg pain with sitting and flexing (her work position).	7 Months	<ul style="list-style-type: none"> Medications Epidural Steroid Injections Physical Therapy 	Moderate right paracentral contained, protrusion at L5-S1	50% Reduction in disc bulge size	90 6 Months	<p>Nov 2008-Ax T2 FRFSE ET-7, TR-1383, TE-29.5 May 2009-Ax T2 FRFSE ET-7, TR-1383, TE-29.5</p>
LM-39 yo male construction worker with axial and leg pain. Also had SI joint syndrome and systemic porphyria with neuropathy related to same.	17 Years	<ul style="list-style-type: none"> Narcotics Epidural Steroid Injections Physical Therapy 	Large right, contained, paracentral protrusion at L5-S1	>75% Reduction in disc bulge size	60 4 Years	<p>Jun 2008-Sag T2 FRFSE FS ET-16, TR-2967, TE-108 Apr 2010-Sag T2 FRFSE FS ET-16, TR-3017, TE-107</p>
MJM-35 yo male who was unable to be managed with epidural steroid injections to primarily axial pain>radicular.	14 Years	<ul style="list-style-type: none"> Medications Epidural Steroid Injections Physical Therapy 	Small central, contained, protrusion at L4-L5	>75% Reduction in disc bulge size	Later developed HNP and needed surgery.	<p>Jul 2008-Sag T2 FRFSE FS ET-6, TR-317, TE-3.1 Sep 2008-Sag T2 FRFSE FS ET-6, TR-317, TE-3.2</p>
ML-23 yo female graduate student with axial LBP, positive L4-S1 two level discography. L5-S1 disc treated with Gen 2 and L4-L5 later treated with Gen 3 procedure.	3 Years	<ul style="list-style-type: none"> Medications Physical Therapy 	Moderate central, contained, protrusion at L4-L5 and L5-S1 with HIZ	50% Reduction in disc bulge size	60 6 Months	<p>Jun 2008-Sag T2 STIR ET-6, TR-4817, TE-48 Aug 2008-Sag T2 STIR ET-6, TR-4817, TE-48</p>
NQ-39 yo female office worker s/p MVC with S1 radiculopathy causing axial and leg symptoms. Had to be delayed in study by > 1 yr due to need for emergent steroid ESI before start.	2 Years	<ul style="list-style-type: none"> Medications Epidural Steroid Injections Physical Therapy Chiropractic 	Moderate central, contained, protrusion at L5-S1	50% Reduction in disc bulge size	100 Leg 70 Axial 2 Years	<p>Sep 2009-Sag T2 STIR ET-12, TR-4167, TE-37 Jun 2011-Sag T2 STIR ET-12, TR-4167, TE-37</p>
JP-28 yo female office worker s/p failed discectomy/laminectomy causing axial> leg symptoms. L5/S1 disc treated with Gen2 protocol and L4-L5 disc treated with Gen 3 protocol.	5 Years	<ul style="list-style-type: none"> Medications Epidural Steroid Injections Physical Therapy 	Moderate right paracentral contained, protrusion at L5-S1, small central contained protrusion at L4-L5	50% Reduction in disc bulge size	80 2 Years	<p>Mar 2007-Ax FRFSE ET-2, TR-6300, TE-153 Jul 2010-Ax FRFSE ET-2, TR-6300, TE-154 Mar 2007-Sag FRFSE ET-2, TR-6300, TE-153 Jul 2010-Sag FRFSE ET-2, TR-6300, TE-153</p>
KG-39 yo female model s/p failed discectomy/laminectomy causing axial and leg symptoms, also had co-existing SI joint syndrome.	6 Years	<ul style="list-style-type: none"> Medications Epidural Steroid Injections Physical Therapy 	Moderate central contained, protrusion at L5-S1.	>75% Reduction in disc bulge size	80 4 Years	<p>Jan 08: Ax STIR ET: 19, TR: 3450.0, TE: 96.1 Feb 09: Ax STIR ET: 15, TR: 3450.0, TE: 96.1 Jan 08: ET: 12, TR: 5500, TE: 47 Feb 09: ET: 12, TR: 5500, TE: 47</p>
EJ-28 yo female who injured back snowboarding, axial and leg pain. S/P failed percutaneous decompression.	3 Years	<ul style="list-style-type: none"> Medications Epidural Steroid Injections Physical Therapy Percutaneous Decompression 	Moderate central broadbased contained, protrusion at L4-L5.	Small Reduction in disc bulge size	40 1 Year	<p>Oct 08: Ax T2 ET: 19, TR: 5533, TE: 102 Aug 2011: Ax T2 TR: 4600, TE: 144</p>
MM-42 yo male office worker inured low back in MVC with axial low back pain. He also had an SI joint injury that was treated, disc outcomes are what he attributed to the disc procedure.	10 Years	<ul style="list-style-type: none"> Medications Epidural Steroid Injections Physical Therapy Medial Branch Blocks SI Joint Injections Ligament Injections 	Small central and right foraminal contained, protrusion at L5-S1.	25-50% Reduction in disc bulge size	80 6 Months	<p>Aug 12 FRFSE - Pre-op ET: 18, TR: 1566.2, TE: 123.0. 6 month Post-op ET: 18, TR: 1563.3, TE: 123.1 Aug 12 FRFSE - Post-op ET: 18, TR: 1566.2, TE: 123.0. 6 month Post-op ET: 18, TR: 1563.3, TE: 123.1</p>
HO-20 yo female college student with axial low back and leg pain who inured low back lifting at age 14. Patient had Gen 2 procedure in 2008 and a second Gen 3 procedure on the same disc in 2009.	6 Years	<ul style="list-style-type: none"> Medications Epidural Steroid Injections Physical Therapy Facet Injections Chiropractic Acupuncture 	Moderate left paracentral contained, protrusion at L5-S1.	25% Reduction in disc bulge size	70 1.5 Years	<p>Change in nerve root position due to 3rd stem cell procedure. Left L5 nerve root was pushed posterior on the before image and now is more anterior in more physiologic position.</p>
RF-31 yo female paralegal with insidious onset axial and leg pain. After her stem cell disc treatment, she was later found to have a multi-factorial pain complex that also included the SI joint, mild central canal stenosis, and facet arthropathy. She received one Gen 2 and one Gen 3 injection into the same disc.	5 Years	<ul style="list-style-type: none"> Medications Epidural Steroid Injections Physical Therapy 	Moderate central contained, protrusion at L4-L5.	No Reduction in disc bulge size	0 3 Years	Post-op Images Not Available
CH-27 yo male with axial low back and leg pain who inured low back dead lifting.	3 Years	<ul style="list-style-type: none"> Medications Traction (Vax-D) Chiropractic Physical Therapy 	Small central contained, protrusion at L4-L5 with HIZ and decreased disc height	No Reduction in disc bulge size	100 6 Months	Post-op Images Not Available
WB-70 yo male with axial low back and hip pain s/p right THR and with chronic left groin pain. Prior to injection of stem cells, rapid loss of disc height at L5-S1 was observed when compared to his prior pre-op MRIs. Multi-factorial pain complex. Multiple spinal levels likely involved, hip arthritis, SI joint pain.	1 Year	<ul style="list-style-type: none"> Medications Epidural Steroid Injections Physical Therapy SI Joint Injection Hip injection Acupuncture 	Broadbased protrusion at L5-S1 with severe DDD, lost disc height and vacuum phenomenon.	No Reduction in disc bulge size	30 4 Years	Post-op Images Not Available
AN-20 yo male with axial low back and leg pain s/p who injured his low back dead lifting from the floor.	6 Months	<ul style="list-style-type: none"> Medications Epidural Steroid Injections Physical Therapy 	Large central broadbased contained, protrusion at L4-L5.	No Reduction in disc bulge size	Decided to pursue microdiscectomy when procedure failed.	<p>Jul 2009 ET: 21, TR: 4000, TE:101 Nov 2009 ET: 21, TR: 4000, TE:101</p>
AE-34 yo female with axial low back with two level DDD as well as facet pain and myofascial pain. Only L5-S1 treated after L5 SNRB showed good pain relief.	2.5 Years	<ul style="list-style-type: none"> Medications IDETC Epidural Steroid Injections Physical Therapy Facet Injection Trigger Point Injections 	Large central broadbased contained, protrusion at L4-L5 and left paracentral at L5-S1 with HIZs.	Small Reduction in disc bulge size Less Modic and Endplate Changes	40 2 Years	<p>Jul 09: FAST T2 TR: 3500, TE: 112 Mar 2010: FAST T2 TR: 3733, TE: 114</p>
SM-48 yo female with axial low back > leg pain with two level disc bulges and myofascial pain. Left SI joint also a pain generator.	3 Years	<ul style="list-style-type: none"> Medications Physical Therapy Acupuncture Chiropractic 	Moderate central contained, protrusion at L4-L5 and small central protrusion at L5-S1, both with HIZs.	No Reduction in disc bulge size	100 3.5 Years	Index debilitating pain is 100% relief. L4-L5 left untreated and patient relates remaining pain to this disc.
AP-33 yo female with axial low back and leg pain s/p MVC. Marked bilateral lateral recess stenosis at L4-L5 and moderate to severe foraminal stenosis at L5-S1. Unable to quit smoking. Required updated epidurals 4 years after disc treatment.	7 Years	<ul style="list-style-type: none"> Medications Physical Therapy Trigger point injection 	Moderate central contained, protrusion at L5-S1 and small central protrusion at L4-L5.	Small Reduction in disc bulge size Increased disc height	20 3 Years	<p>Mar 08: FONAR T2 TR: 1734, TE: 140 Jul 2013: T2 FRFSE: ET-26 TR: 3676, TE: 99</p>
NP-46 yo male with axial low back and leg pain. Had short-term relief with epidural performed by us prior to his disc procedure, this confirmed L5-S1 disc and radiculopathy as pain generator.	3 Years	<ul style="list-style-type: none"> Medications Physical Therapy Chiropractic 	Moderate central broadbased contained, protrusion at L5-S1. Small central protrusion at L4-L5.	No Reduction in disc bulge size	60 3 Years	Post-op Images Not Available
KS-31 yo male born with severe sacralization of L5-S1 and S1 motor symptoms since childhood. Severe central sensitization (i.e. unable to tolerate injection procedures without TIVA). Lowest mobile disc identified as pain generator before procedure. Patient believed sacralized segment was pain generator, but unable to access.	20 Years	<ul style="list-style-type: none"> Medications Physical Therapy Chiropractic 	Normal L5-S1 disc (lowest mobile segment-sacralized lower segment) with discogenic Pain.	No Reduction in disc bulge size	50 4 Years	Post-op Images Not Available
KB-39 yo male with axial LBP and buttock pain. Radiated down left leg. S/p L3-L4 and L4-L5 laminectomy/discectomy with perineural fibrosis. Failed multiple aggressive non-invasive interventions prior to disc treatment.	1.5 Years	<ul style="list-style-type: none"> Medications Physical Therapy Lysis of adhesions Epidural steroid injections IDETC 	Recurrent disc herniation at L4-L5 s/p laminectomy/discectomy with L5 perineural fibrosis..	No Reduction in disc bulge size	0 4 Years	Post-op Images Not Available
SS-59 yo female with progressive axial LBP with radiation to the thigh. L5-S1 bilateral foraminal stenosis, facet arthropathy, bilateral L4-L5 foraminal stenosis.	2 Years	<ul style="list-style-type: none"> Medications Physical Therapy Massage Epidural steroid injections Inversion Table 	Large central broadbased contained disc protrusion with HIZ and severe loss of disc height at L5-S1.	No Reduction in disc bulge size	90 6 Months	Pre/Post-op Images Not Available
JP-35 yo male with axial LBP with radiation to bilateral calves. L3-L4 mild foraminal stenosis (level not treated).	1.5 Years	<ul style="list-style-type: none"> Medications Physical Therapy Massage Ligament Injections Acupuncture 	Small central contained, protrusion at L4-L5 and small central protrusion at L3-L4, both with HIZs.	No Reduction in disc bulge size	80 4 Years	Post-op Images Not Available
SB-35 yo male with leg/hip with radiation to leg/foot s/p MVC. Also had neck pain. Facet arthropathy L4-L5 and this level also had bulge with HIZ. Only L5-S1 disc treated.	3 Years	<ul style="list-style-type: none"> Medications Physical Therapy 	Large central contained, protrusion at L5-S1 and small central protrusion at L5-L5.	50% Reduction in disc bulge size	90 4 Years	<p>Dec 09: Sag T2 TR: 3550, TE: 120 Sep 2010: FRFSE: 3100, TE: 103 Dec 09: Ax T2 TR: 7900, TE: 122 Sep 09: Ax T2 TR: 7900, TE: 114</p>
MF-23 yo male with axial low back pain and bilateral leg pain.	1.5 Years	<ul style="list-style-type: none"> Medications Physical Therapy Traction (DRX-9000) Inversion Traction 	Large left disc extrusion at L4-L5 and small protrusion at L5-S1 (both compressing descending nerves).	No Reduction in disc bulge size	Decided to pursue disc replacement when procedure failed.	Post-op Images Not Available
SH-30 yo male with axial low back pain and bilateral leg pain.	4 Years	<ul style="list-style-type: none"> Medications Physical Therapy Epidural Steroid Injections Massage 	Small left disc protrusion at L5-S1	No Reduction in disc bulge size	0 4 Years	Post-op Images Not Available

All Patient Likert Scores Graphed by Time Points



Mean Improvement (Likert): **59.7%**
 Mean time since procedure: **2.3 Years**