

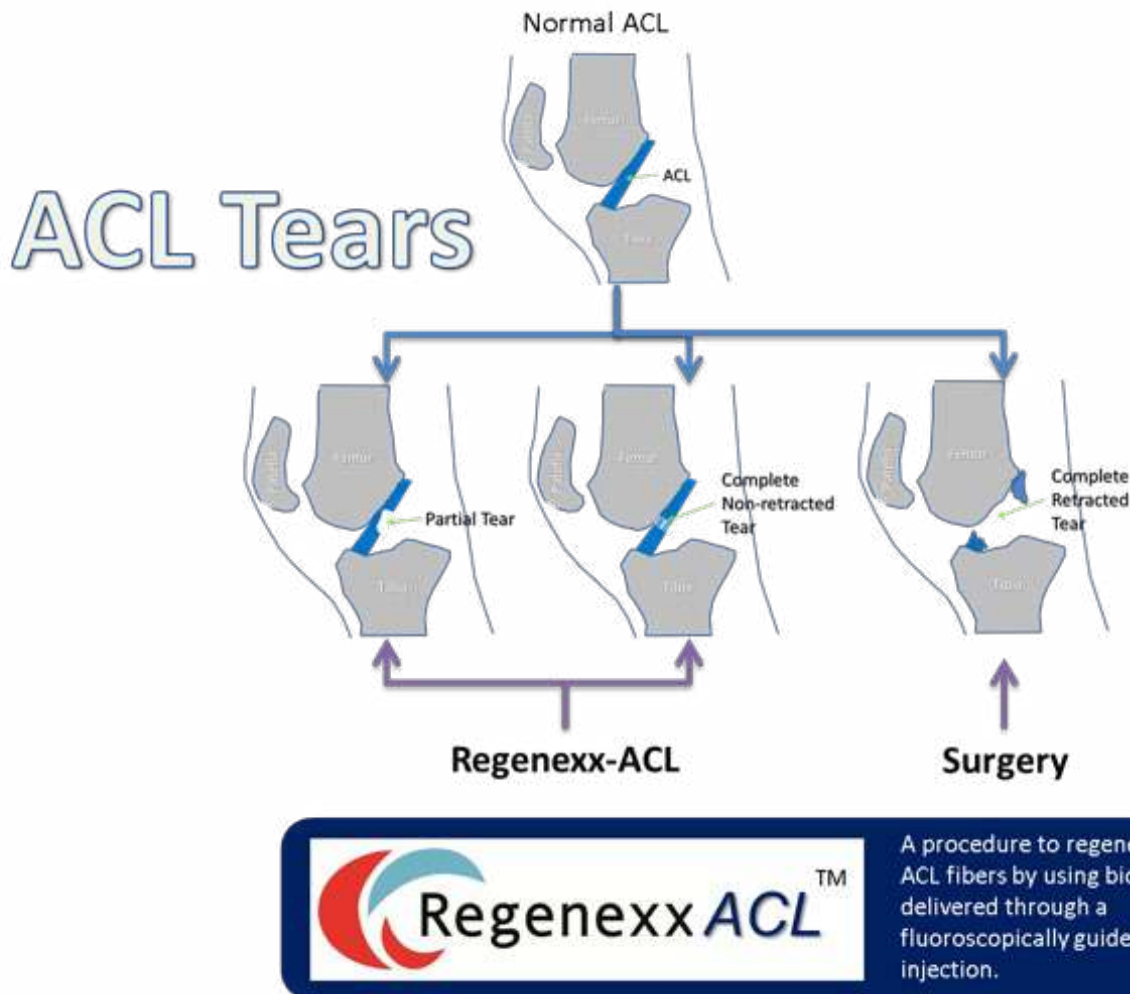
# Regenexx<sup>®</sup>

## **Regenexx-ACL**

Do You Really Need Surgery to Help an ACL Tear?

Christopher J. Centeno, MD

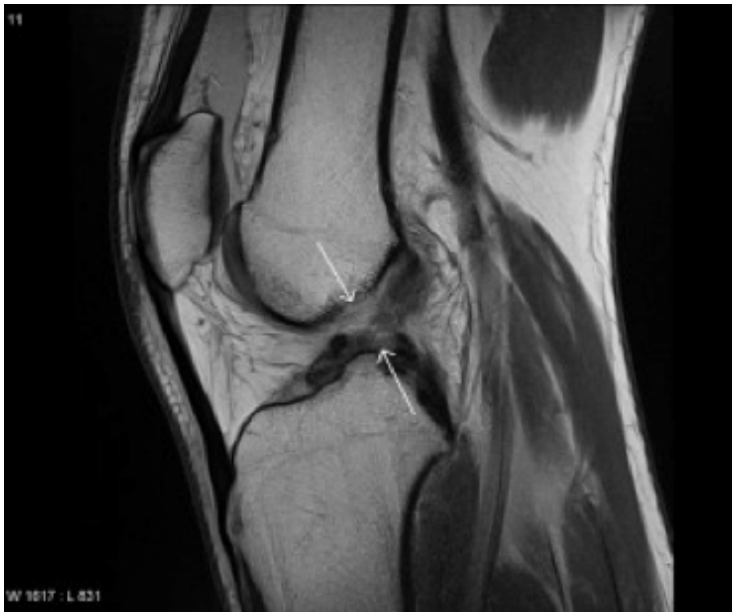## The Types of ACL Tears



There are three very different types of tears, and yet most patients only hear of two. First, there is a partial ACL tear (above left). These [ACL tears don't require surgery and, in our experience, can be easily fixed with simple injections under x-ray guidance](#). The second is a complete retracted tear (above right). This is where the ligament has snapped back like a rubber band. Most patients believe they have this kind of tear when they see the phrase "complete tear" on their MRI reports, but unless you also see the word "retracted," you don't have this kind of tear. This brings us to the third type which is a complete nonretracted tear (above middle). On an MRI of this tear, it looks like the fibers are torn all the way through the ligament, but there's still something holding the ligament together because it hasn't snapped back. We see lots of complete nonretracted [ACL tears, and we have fixed many through injection without the need for surgery](#).

If you have a complete tear, check your MRI report for the word “retracted.” If it is not there, then the ACL tear is not retracted (don’t be dismayed if you don’t see the term “nonretracted” as radiologists only sometimes use the term) and may be easily fixed using the Regenexx-ACL stem cell procedure.

## **Surgery Usually Not Needed for a Partial Tear**



The ACL is one of the main ligaments in the knee that helps to stabilize it between the femur and tibia in a front-back direction. When this ligament gets injured, many patients opt to have it replaced. The logic presented is that without a strong ligament, especially when the patient is active, the knee may be prone to more damage. In addition, the wisdom has been that even a partial tear was unlikely to heal.

However, a research study questions that concept. [In this study athletes with ACL tears were randomly assigned to either have surgery to replace the ligament or to follow a strict physical therapy program.](#) Sixty percent of the athletes that didn’t get the knee surgery never needed to have the ACL replaced. This brings up an important point: we have seen more patients getting ACL surgery to replace the ligament, even with partial tears. We would advocate that patients with partial tears wait to see if the ligament heals, and if it doesn’t heal, many nonsurgical options exist that we believe should be tried before surgical replacement of the ACL. These include [prolotherapy](#) (study by Reeves showing effectiveness) or [PRP injections \(platelet rich plasma taken from a vein, spun down, and injected into the knee\)](#). We believe these injections should be guided by imaging (x-ray or ultrasound). We have also helped patients with [complete \(nonretracted\) or partial ACL tears by injecting their own stem cells into the tears.](#)

## The ACL After Surgery Is Never Like the Original

Almost every patient I have ever met believes his or her knee will be normal again after recovering from ACL surgery. The ACL is a major stabilizer of the knee and is often injured in sports. Most patients believe that when they injure their ACL ligaments, they can just get a new one—no harm, no foul. But the reality is, [there are many surgery complications](#) and the [new ACL ligament is nothing like the original](#).

We often see lax ACLs as a result of ACL surgery. [One study on ACL allografts](#) may explain why; it found that in certain patients with allografts (an ACL that came from another patient), the ligaments were lax when there was cellular evidence that the graft was being rejected by the patient.

[An interesting study examined the muscle activation and biomechanics in ACL surgery patients at about an average of 5 years after surgery.](#) The study authors noted that many of the muscles that help stabilize the knee are overactive after [ACL surgery](#). The patients also placed less weight on the ACL repaired knee and even had abnormal firing of the gluteal muscles and calf muscles. Women had fewer abnormal muscle contractions than men, but the women also placed less force on the ACL surgery knee.

Why doesn't a knee with a new ACL have normal muscle activation patterns? It's very difficult to replace the ACL surgically and have the same biomechanical properties as the original ACL. This study fits with others showing that [ACL replacement surgery can lead to more arthritis or that ACL surgery doesn't prevent the onset of arthritis](#).

If the ACL is completely torn and retracted, you may have a very difficult decision on whether to repair the ACL or leave it alone. More importantly, if your ACL is a partial tear or a complete tear that's still in place (the two ends aren't retracted and pulled back like a snapped rubber band), then you may consider the Regenexx-ACL [stem cell placement into the ACL via injection rather than surgery](#).

## More Studies on the ACL Following Surgery

[One study](#) showed that the new and improved “double bundle” ACL surgery isn't all that great. The concept is that since the ACL ligament has two parts, if we replace both parts (bundles), then the knee will be better off. Regrettably, these researchers didn't find any reduction in knee arthritis or function four years after the new surgery when compared to the old method.

[A second study](#) looked at whether female athletes, who believed they were healed after an ACL surgery, could perform a diagonal leap and land the same way as athletes with a normal ACL. While both groups did a forward leap about the same, leaping diagonally and landing was much worse in the ACL surgery group.

A [third study](#) looked at neuromuscular control tasks—namely those that involved balance. Again, patients who had undergone ACL reconstruction surgery had abnormal balance even at one year post surgery. Finally, on a slightly different note, in [another study](#) younger patients under age 25 were four times more likely to tear their ACL again after reconstruction surgery.

Conclusion: We still don't have the technology to fix a torn ACL so that it performs like the original. As a result, explore biologic options to heal the ACL.

### **Risk of Reinjuries for Athletes after ACL Surgery**

There was an [interesting study](#) presented at the American Academy of Orthopedic Sports Medicine that got little press. A physical therapist and colleagues studied the incidence rate of a second ACL injury in the two years following ACL reconstruction surgery and a return to sports in a young, active population. They looked at re-tear of the graft and whether the unoperated side had an injury during recovery. In their prospective study, the researchers enrolled 78 young patients (59 women, 19 men, aged 10 years to 25 years) who underwent ACL surgery and returned to a sport and compared them to 47 healthy, control athletes without a history of ACL problems.

Each athlete was followed for injury, and data was collected on the time spent playing sports. Paterno and colleagues found that 23 patients in the ACL reconstruction group and four athletes in the uninjured group had an ACL injury during the year-long period. The overall rate of a second ACL injury within 24 months after ACL surgery and return to sports was nearly 6 times greater than the uninjured group.

[Overall, 29.5% of athletes had a second ACL injury within 24 months of their return to a sport](#) with 20.5% having a new injury to the other side and 9% having a graft re-tear injury. More women (23.7%) had a new nonsurgical-side tear than men (10.5%). This begs the question of whether biomechanical issues with the ACL-repair knee are leading to more stress on the other knee.

Earlier in the report, we discussed that [an ACL surgical replacement isn't like the original ACL because the grafts go in at a much steeper angle](#). This could be the cause of all these second injuries. The ACL is also rich in position sensors that help guide the muscles of the lower body in accurate movement. Removing it may get rid of all of that normal position sense and impact the other knee. [One study](#) showed that patients with an ACL injury had just as much loss of position sense in their good knee as their ACL-injured knee, so what happens on one side seems to impact the other.

Conclusion: Getting one knee ACL “fixed” surgically appears to markedly increase the chance that the other knee will be injured. This could be due to either the ACL injury itself or the ACL surgery. Perhaps it would be best to heal the ACL (if possible) rather than remove it, as removing the ligament and installing one that isn’t like the original can’t be the best option.

### **Preinjury Sports Levels in Athletes Unlikely with Surgery**

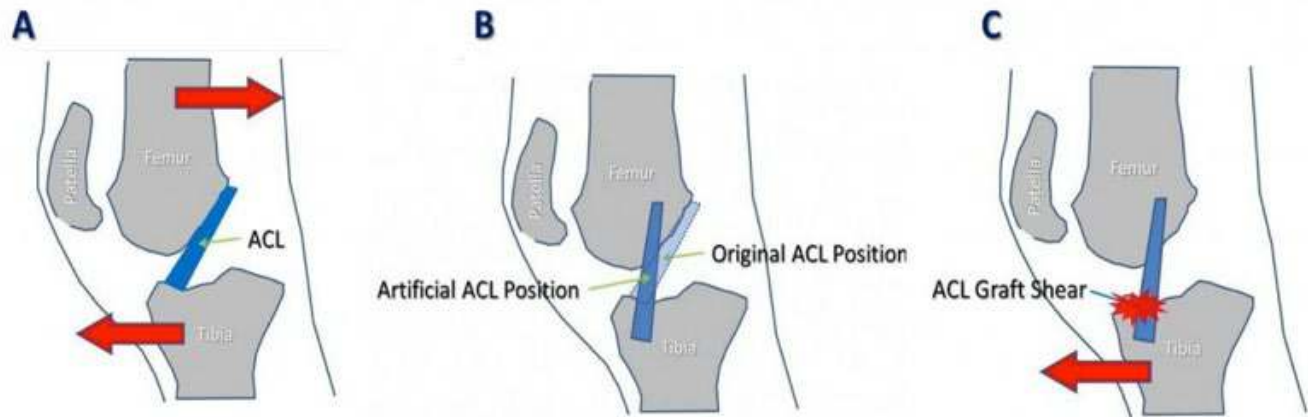
Most athletes believe that when they have a torn ACL ligament, surgical reconstruction will make their knees like new again. This is not true. A [recent study questions this assumption, reporting that about two-thirds of 500 athletes failed to achieve their preinjury level of play despite being a year out from ACL surgery](#). In the study men were more likely than women to return to sports, as were patients with a [good hop test](#). The study concluded that more than a year of rehab is needed to get back to sports, but [we believe if you’re not able to get back to sports a year out from ACL surgery](#), then it’s unlikely to happen.

This brings up an important point. We’re still routinely replacing [ACLs that are partially torn, and in our clinical experience, these injuries can often be successfully treated through a needle](#), without the need to remove the existing ACL and put in a new one. If most of the athletes we treat with ACL surgery never get back to sports—and that’s the reason they’re having the surgery—[why are we surgically removing these ligaments and replacing them?](#) Good question.

We believe that the balance of the data supports [surgically replacing a completely torn and retracted ACL to prevent long-term instability that will lead to eventual knee arthritis](#). However, we also believe that injection therapies, rather than surgical replacement, are likely the first-line option for partially torn or nonretracted ACLs. [Here are examples of what can happen when cells are injected into the ACL of a sidelined young soccer star with a partially torn ligament and into the ACL of a college-football scholarship athlete with a torn ligament](#).

Conclusion: Once an ACL is torn, the athlete needs to consider all the options carefully, as surgical reconstruction of the ACL usually doesn’t result in a return to sports.

## Aggressive PT after ACL Surgery Makes No Difference



As you may know, [we're not big fans of surgery to replace torn ACLs](#). This is because the [ligament repair bears no resemblance to the original](#). In addition, [recent research has shown that the chances of injuring the opposite, normal knee significantly increase after an ACL surgery, likely due to abnormal biomechanics in the surgical knee](#). So the outcome of a [new study](#) that looked at aggressive rehab after an ACL reconstruction surgery was no surprise.

The authors randomized 36 patients who had their ACLs reconstructed using their hamstring tendons into either very aggressive physical therapy or into light physical therapy. The results? There were no differences between the groups on any measure. Why is this not surprising? In this early phase of care after surgery (up to six months), the ACL graft is likely strong, and it's tightness is all that matters for knee stability. So while having strong muscles might help in the long run, an artificial [ACL placed at the wrong angle \(as all artificial ACLs are—see images A and B above\)](#) will trump muscular activity for stability. Now draw this out a few years, and you might see differences. In our clinical experience, the graft shear of the artificial ACL's vertical positioning will eventually loosen the new ACL (see C above). So perhaps getting stronger and staying stronger would make more of a difference over longer periods of time.

Conclusion: Aggressive PT after ACL surgery doesn't seem to make a big difference in short-term outcome. Having said that, we ask another question: [why allow your ACL to be surgically removed in the first place if there's a chance at healing it?](#)



## Knee Cartilage Worsens Following ACL Surgery

There are about 100,000 ACL tears each year in the United States, and many of them get a new surgically implanted ACL followed by a long surgery recovery. [One study](#) shows that the cartilage in the knee isn't well protected by the new surgically replaced ACL. In this new research they took 15 ACL surgery patients and imaged them with a 3.0T research grade MRI at one and two years post procedure. They measured important MRI values that indicate good and healthy cartilage. What did they find? Regrettably, most of the cartilage in the ACL-reconstructed knees was worse off after two years when compared to the cartilage of healthy patients. Had maybe just one area been worse, you could theorize that this spot was perhaps hurt in the original ACL injury. However, the fact that almost all areas measured were worse indicates that something else is going on. What?

It's possible that the abnormal motion of the knee due to the steeply angled ACL replacement (discussed earlier in this report) is causing excessive forces on the cartilage, leading to breakdown.

Conclusion: [Avoid ACL replacement and ACL surgery recovery where possible](#). We've had good luck with fixing partially torn and nonretracted complete tears through a needle with stem cells. In addition, some studies show that physical therapy may work just as well as surgery in the short to medium term.

## Women Have a Higher Risk of Arthritis after ACL Surgery

The reason we don't like our patients getting a partially torn ACL removed and replaced is that despite reconstruction of the ACL, the knee isn't completely normal. [A study that looked at a sophisticated analysis of walking patterns in patients with ACL surgical reconstruction](#) supports this concept. Women who had ACL surgery had a tendency to shift their knee inward (adduction) during walking, which the study authors believed could lead to a higher rate of knee arthritis. Men didn't have this same problem with walking after an ACL surgery. [This is consistent with another study which found general biomechanical problems for patients with reconstructed ACLs](#).

## Single-Legged Hop Test Predicts the Need for ACL Surgery

If you've recently injured your ACL, a simple test may predict if you would do well without surgery. [One study investigated whether a single-legged hop test for distance could tell who would do well one year after their ACL injury](#). The study tested 91 patients about two months after an ACL injury, who didn't opt for ACL reconstruction surgery. Eighty-nine percent of these same patients were then retested about a year later. It turns out that the single hop test for distance predicted those patients who were more functional at a year out. In addition, more women had difficulty at that point than did men.



To perform this test, stand on one leg with your foot on a starting line (some fixed point you can measure from). Take a maximal hop forward, landing on the same leg (along a straight line). Arms may swing freely to assist, may rest at your sides, or may be placed behind the back. The distance is measured from the starting line to where the back of the heel lands. Landing position must be held for two seconds with no loss of balance or extra steps.

The hop is scored by comparing the bad leg to the good leg. For example, if you could hop 3 feet on the bad leg and 6 feet on the good leg, then you would divide 3 by 6 to get 0.50 and multiply by 100 to get a percentage of the good-leg hop. In this case that would be 50%. In this study the cutoff for someone doing well a year out from their injury was an 88% hop on the bad leg (as compared to the good-leg hop) when measured at about two months after injury.

Conclusion: If you've recently injured your ACL, you may want to perform this simple test to see if you can avoid ACL surgery

### Healing ACL Tears without Surgery

Over the past few years, we've seen [MRI evidence of ACL healing with stem cell treatment](#). Our website shares ACL images that show improvements with just an injection of stem cells, including a [14-month post-injection MRI](#), a [5-month post-injection MRI](#), and a [4-month post-injection MRI](#).

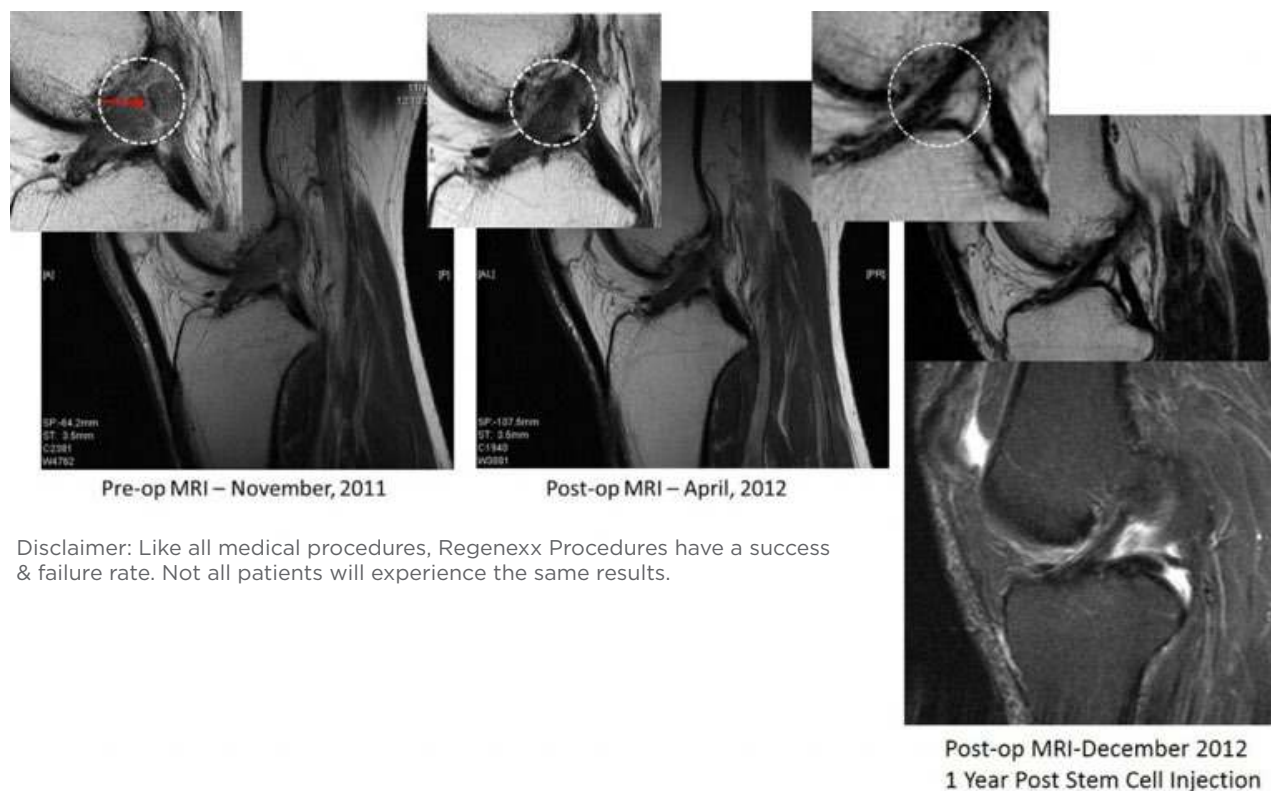ACL surgery can possibly be avoided by using your own stem cells to heal your knee. With our [new technology, we can perform an exacting injection of the patient's own stem cells directly into the torn ACL](#). When we first began this type of therapy, we figured that only about one in three ACL tears were good candidates. However, since then we've routinely seen good evidence of healing of complete ACL tears and now include patients with complete nonretracted and partially retracted ACL tears.

If all of the less-invasive injection options fail, then [replacing the ligament may be needed](#). However, [Frobell's study](#) shows that for many, including athletes, with ACL tears, just letting the ACL heal over time may also be enough.

Conclusion: The knee, like any human joint, is a complex dance of stability and precisely controlled movement. The ACL is a taut band that stabilizes the knee in a front-back direction and contributes to this finely tuned movement. Due to the complications that can develop and the fact that the knee will never perform like the original following ACL surgery, less invasive options should be considered before surgery.

## Stem Cell Case Studies

Patient with Complete Nonretracted ACL Tear



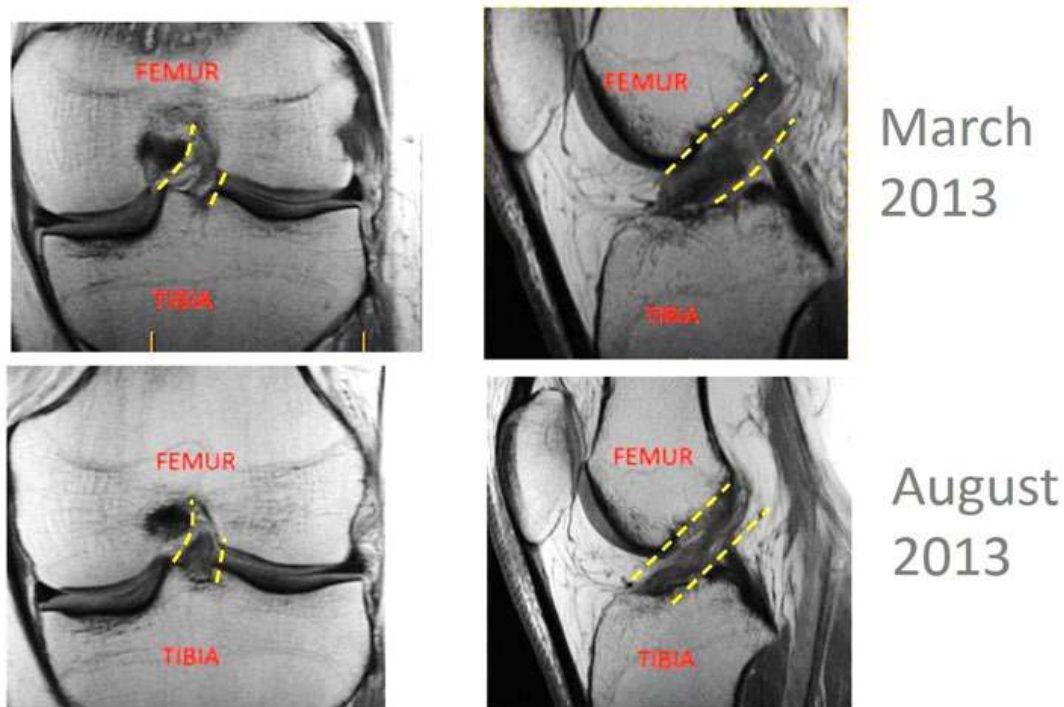
Disclaimer: Like all medical procedures, Regenexx Procedures have a success & failure rate. Not all patients will experience the same results.

Above you'll find the knee MRI of a patient who had a [complete nonretracted ACL tear](#), and [treated it with a stem cell injection](#). You can see his preoperative MRI to the left with the obvious gap in the ACL (red arrow). His 5-month postoperative MRI is in the middle without the gap in the ACL. His 14-month MRI is to the right, showing what appears to be a normal appearing ACL. How was this done? This result wasn't accomplished via surgery but by an [extracting an injection of the patient's own stem cells into the ACL](#) using the Regenexx-SD procedure.

[At one year after receiving a Regenexx-SD stem cell procedure, over 60% of patients who responded reported greater than 50% relief, and at four years, this number jumps to over 90% of patients.](#)

Conclusion: We've seen good results on yet another ACL tear treated with stem cells, and this helps patients avoid the need for a very invasive ACL surgery. Not all patients who have complete nonretracted ACL tears should expect a complete recovery or that their MRI will show complete or near-complete healing.

## Physician-Patient Benefits from Regenexx-ACL Procedure



With surgery ACL repair recovery time can be a long affair. First, somebody surgically removes the torn ACL and then drills holes in the bone to anchor a replacement ACL (so there is really no repair). You spend about a month on crutches and then begin a long and protracted rehab program. Is there a better way?

How about using stem cells to repair the ACL that's already there rather than tearing it out? [We can inject stem cells using the Regenexx-ACL procedure under exacting fluoroscopic guidance.](#) Many ACLs that have been repaired using stem cells have a much better appearance on postinjection MRIs, and on exam these knees go from unstable to more stable.

The example above is a physician who was treated with the Regenexx-ACL procedure. He had no surgery, and he had no ACL recovery time; he got an injection and continued with his usual activities. The before picture above (March 2013) shows a very tattered and exploded-appearing ACL (inside the yellow dashed lines). Now compare that appearance to the after images (August 2013). This ACL now looks like a tight rope. It's denser (darker), more like a normal ACL.

We now routinely see these images showing MRI evidence of ACL repair with the Regenexx-ACL procedure. Nobody else has developed a technique to accurately place stem cells in the ACL—more of the kinds of innovations you can expect from the first in the orthopedic stem cell field.

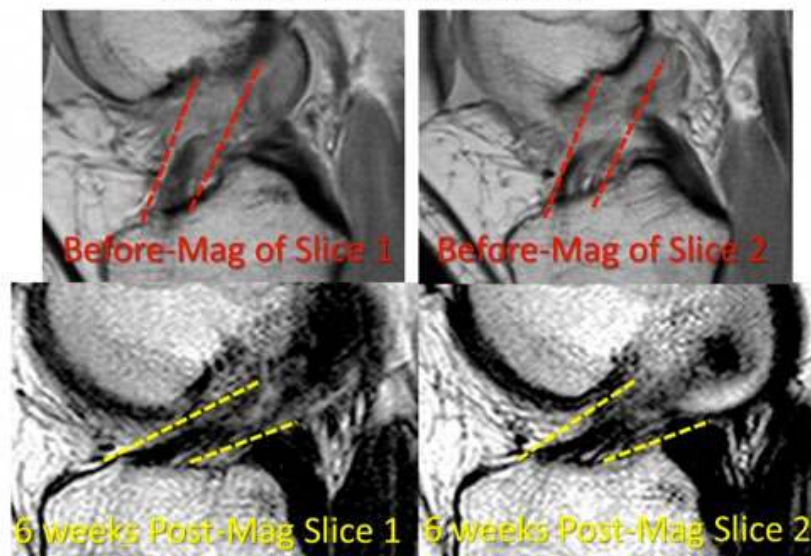
## Elite Soccer Player Gets Help with Regenexx-ACL

We saw an elite soccer player who had torn her ACL. Perhaps a better phrase is actually shredded her ACL. She wanted to avoid ACL surgery, so she underwent an injection of her own stem cells into her ACL. The image on page 11 shows where the ACL fibers travel (yellow dashed lines). They should be tight and all heading in the same diagonal direction. Instead, what you see is a tangled mess of torn and hectic fibers. Now look at the post treatment MRI on the right. Between the yellow lines, you see nice fibers that all go the same diagonal direction.

While she will likely need a second stem cell injection due to the severity of her shredded ACL (to get these fibers denser), she's on her way to avoiding surgery. Rather than extensive downtime on crutches and months spent trying to rehabilitate her knee, she's been able to exercise. There's now a very good chance she'll get to [keep her original ACL rather than undergoing surgical removal and then graft insertion at way too steep an angle](#). In addition, we hope that with her original ACL intact, [she will be able to dodge the early onset of arthritis that often plagues young women who have ACL surgeries](#).

## Fourteen-Year-Old Soccer Star and Regenexx-ACL

ACL ligament fibers are the dark signal inside the red (before) and yellow (after) dashed lines.



This 14-year-old soccer star, like many girls playing soccer today, blew out her ACL with few detectable fibers on MRI that connected into her femoral insertion of the ligament. She was told that Regenexx ACL therapy had a high risk of failure due to the size of the tear, but her physician understood that [a 14-year-old who has her ACL removed and replaced surgically will more than likely have knee arthritis by the time she's 30](#). So they elected to try the Regenexx ACL procedure.

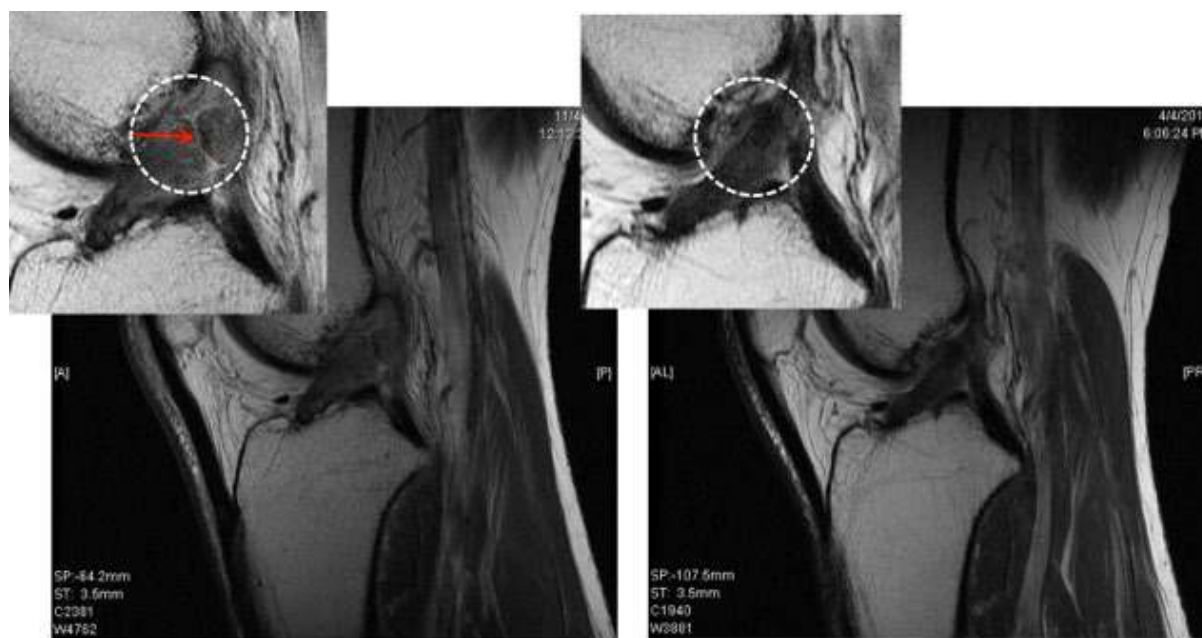


The result at six weeks after the stem cell injection is above. Note that on the before image, the red dashed lines outline the dark ACL, which only extends part of the way up (it should be almost black and extend the full length inside the lines). In addition, the ligament is loose, and its angle is wrong.

In the after image, the ligament now extends the full length, and the angle has changed (the ligament now lies a bit more horizontal). Why did the ligament angle change? Her ACL is now tight (like it should be), so after the treatment it lies at a more normal horizontal angle.

Conclusion: We're now routinely helping many patients avoid the need for ACL surgery and dramatically shortening recovery times by allowing patients to keep their own ACLs.

### Fifty-Two-Year-Old Male with History of Tears



Pre-op MRI – November, 2011

Post-op MRI – April, 2012

### Michael (52 yo, male)

Regenexx-SD Treatment  
December, 2011

Michael is a 52-year-old male with history of a meniscus tear and an ACL tear. He injured his ACL playing basketball and was told he needed to get the ACL removed and replaced. Not wanting major surgery and looking for an alternative, he found our clinic and treated his ACL and meniscus tear with the Regenexx-SD procedure, [placing the patient's own stem cells into the ACL using fluoroscopic guidance](#).

His pre- and post-MRI are above (stem cell procedure was in December 2011). Note the preprocedure MRI shows a clear break in the ACL (indicated by the red arrow). While these results are not necessarily typical, note the same ligament about five months after the injection, which shows no break. We're pleased that Michael achieved these results without surgery or major downtime with just an injection of his own stem cells into the ACL.

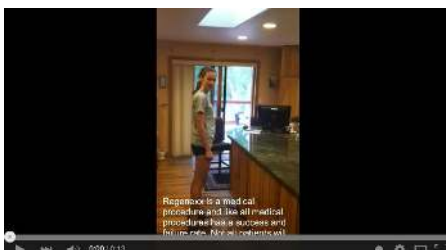Conclusion: We've successfully treated other [patients with ACL tears without surgery](#) and feel that most of these partial to complete nonretracted ACL tears can be helped though injection.

## 17-Year-Old Soccer Star Shines Again after Regenexx-ACL

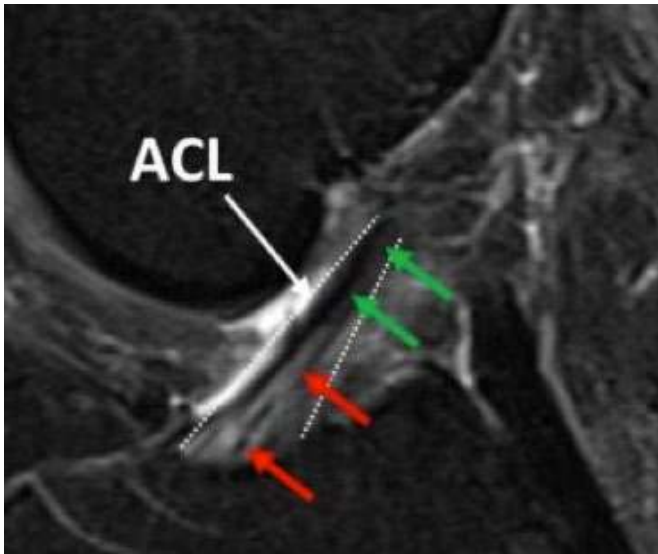
Female soccer players get a lot of ACL injuries. [Women athletes have a two to three times higher rate of injuring their ACL when compared to men.](#) In addition to [two-thirds of athletes not returning to preinjury sports levels after surgery, women are more prone to knee arthritis after ACL reconstruction surgery.](#) So for many girls who injure their ACL while playing soccer and get it "fixed" with surgery, this is a career-ending injury or [one that will eventually lead to the early onset of knee arthritis.](#)

A seventeen-year-old elite women's soccer player injured her ACL, and her parents (her dad is a physical therapist) immediately knew that if she underwent removal of the stretched ligament and surgical replacement, there was a high likelihood that her soccer star wouldn't shine again. They also had concerns for her future, as a thirty-year-old with knee arthritis has few options. As a result they went searching for less invasive ways to treat a stretched ACL. [We have pioneered using C-arm fluoroscopy \(the same type of imaging used for many cardiac stenting procedures\) to inject stem cells into the ACL, replacing the need for more invasive surgery in many patients.](#)

Prior to her Regenexx-SCP procedure where stem cells and platelets were placed into her ACL and patellar tendon, the patient had difficulty climbing stairs and playing tag with friends, and, hence, was not capable of playing soccer at an elite level. Rather than an invasive surgery where her loose ACL ligament was removed and surgically replaced, she underwent x-ray and ultrasound-guided specific injections of stem cells and platelets into her ACL and patellar tendon. Four weeks after the procedure, she reported 100% relief of pain. However, what got our attention was the video below. Watch the soccer star perform a standing vertical jump to a counter top (maybe three feet?). It looks like her function has returned in a big way and that her soccer star will finally burn brightly again.



## Sub-surgical ACL Instability Can Go Undetected



One patient had a knee MRI that demonstrated a significant posterior-medial meniscus tear and a smaller lateral meniscus tear. There was absolutely no mention of his ACL in his MRI report. One surgeon had told the patient he had a [knee plica syndrome](#) that would need surgery. A second surgeon said he would take out 50% of the medial meniscus. Finally, a third surgeon told him that surgery wouldn't help. The patient understood that [taking out the meniscus would leave his knee less protected and cause more arthritis in the long run](#).

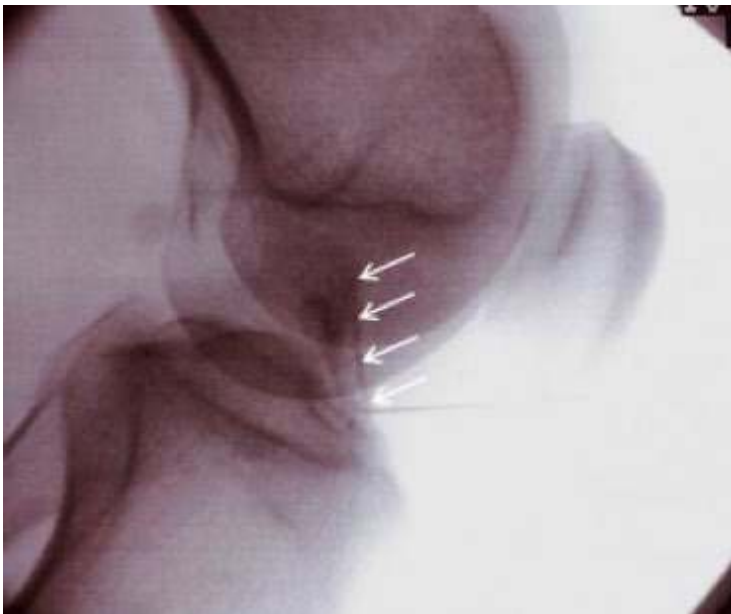When he had his phone review to determine his candidacy for our knee stem cell procedure, I noted his MRI did show a bright area in the ACL where it anchors in the tibia. On his MRI image above, note that in this water-based T2 FAT-SAT image, the ACL (course delineated by the dashed white lines) has a normal dark signal at the top (green arrows) and a brighter signal toward the bottom (red arrows). The areas marked by the red arrows aren't at all normal and are swollen (fluid shows up as a lighter color on these knee FAT-SAT MRI images). This light area in the otherwise dark ACL indicates a clear stretch injury within the ACL.

Despite the clear abnormality, the radiologist didn't read this finding. The patient also reported his [knee felt loose and unstable—a clear sign of instability due to a loose ligament](#). None of the surgeons he consulted mentioned the MRI changes, told him his ACL was loose, or discussed his recovery plan from this stretched ACL. How did the knee look on examination? On exam it was obvious his ACL was lax as the tibia pulled forward much more on that side. [We used a device to measure the movement in his knee allowed by the ACL](#), which was about 4.5 mm on the injured knee compared to half that amount found on testing the other knee. Again, clear signs of ACL laxity.



We see this problem in the clinic quite a bit—the lack of diagnosis of mild to moderate stretch injuries of key knee ligaments such as the ACL. Why does this important finding go unnoticed? We believe some radiologists don't report these loose ACLs because they consider this finding to be just part and parcel of an arthritic knee. So while they may see the abnormality, they don't consider it noteworthy. [We also believe many surgeons don't comment on the ACL laxity because it isn't enough to warrant an ACL replacement surgery.](#)

Despite there not being enough laxity to require surgery, [the laxity leads to significant problems such as additional swelling and arthritis in the joint.](#) What's the solution? If regenerative-medicine treatment is considered, the ACL needs to be treated as well. In this patient a C-arm fluoroscopy to inject the ACL was used along with an ultrasound to inject the meniscus tear. In the ACL injection image below, note the darker radiographic contrast tracking up the ACL ligament (white arrows).



[There is no way to accurately inject the ACL without a C-arm fluoroscope.](#) As an example, when we use contrast dye that shows up as dark on the x-ray (as above), an inexperienced physician using x-ray guidance is actually in the ACL about 1 in 10 times. It's only once the physician learns this specific ACL-injection technique developed by our clinic that he or she can accurately place cells in the ACL tendon sheath. In contrast, getting into this ligament blind without imaging would be a crapshoot at best, just as injecting the ligament with ultrasound would be difficult. [This is because the ligament is buried in a bony tunnel \(trochlear groove\),](#) and ultrasound works by bouncing sound waves off the structure that must return to the machine to be turned into an image.

Does your knee have a loose ligament that no one has diagnosed? Does your MRI show problems within the ACL that weren't read by the radiologist? We observe undiagnosed loose ligaments often enough for us to believe that there are many patients with loose ligaments perpetuating their knee problems who are unaware of the problem. Injecting stem cells or PRP into these joints is unlikely to help until the ligament issues are identified and specifically targeted with treatment.

## What Our Regenexx-ACL Stem Cell Patients Say

Disclaimer: Like all medical procedures, Regenexx Procedures have a success & failure rate. Not all patients will experience the same results.

### Two Years after Knee Stem Cell Injections and Still Running

*I sent in your survey results already. I just have a few questions. First of all I am feeling fine. I have no problems with my knee at all. I do everything I want and more except run. I was always getting running injuries like a pulled hamstring or something which always resulted in some period of recovery and now I have had the longest period of no problems in years, so even though I loved running I can do everything else and have gotten in real good shape (I lost 15 lbs). So running has been put on the back burner. I do stay away from any exercise that might re injure my knee like squats etc. also. I can run and have done an easy mile or so with no problem but the next day I would occasionally feel a slight twinge (which was probably nothing) and for now its good enough to know I can run for a bus without thinking...*

### Helping a Soccer Player with Knee Meniscus Tears Get His Game Back with Stem Cells

*As for my current situation, so far better. Yesterday was my 3rd soccer game I played. First 2 games I played keeper and last night 1st half player on field. I ran and felt good, and today for me was the key cause normally before the injections, after running the next day pain would kick in big time. Today and since I've been running and playing soccer, I am pretty much pain free. Long story short there is a major difference.*

### Healing Another Knee ACL Ligament with Stem Cells

*By 6 weeks post procedure: I was able to walk unbraced, full weight bearing, no instability. Range of motion was in the 70% range. I was able to straighten to a few inches off the floor if sitting down, I was not able to get into a full squat or sit fully on my feet. I began walking 3-5 miles daily, no swelling, and no instability, there were some sharp pains here and there in the front of the knee to the right bottom of knee cap (toward the inner knee).*

*Currently @ 4.5 months out:*

- *There is zero instability. I have experienced zero giving way.*

- *I have not tried anything harder than walking for distance / biking for distance- meaning no lateral movement sports yet because I want a confirmed MRI before engaging.*
- *I have hiked up and down some rooty hills in the woods with no issues. Downhill I hear is the worst on an ACL, I can go straight down a steep hill with 0 problems, including at a light jog. I can do jumping jacks. I have played chasing games with my kids around chairs and all around the house where you have to run sort of sideways to make it around turns, I am not going at full speed, but even at heavier than a jog, there have been no stability issues.*
- *I have been on the beach with no stability issues*
- *In June, I shoveled up and moved a tree, with jumping onto the shovel to get leverage under the tree with no stability issues*
- *The pain in the front right inner portion of the knee is no longer sharp, I do still feel 'something' there, but its harder to identify*
- *I can squat down to the floor and get back up without arm assistance, and I can straighten my leg fully. I can hop for distance to a similar distance on both legs, I can stand on one foot, I can cross-over hop.*
- *I can sit on my knees legs bent, but there is still a slight differential in the treated knee of about maybe a centimeter where I am not able to put 100% weight on the treated side, but its really close*
- *Overall I would say I am at 90ish%, with some stuff still going on. I would classify the 'stuff' as follows: 1. The treated knee has a heaviness feeling to it that the untreated knee does not have; 2. Sometimes I do not feel that I am walking with the same gait on both sides, or if standing still balancing the same on both sides; 3. Humidity seems to affect how much I feel any of these things. Today there is no humidity and treated knee feels near normal.*

### **Helping a Hiker's Knee without Stem Cells**

*30 miles 5200 feet in elevation gain 30 pound pack three days on the Continental Divide Trail at elevations up to 12,500 feet. It's hard to believe that six months ago before I walked into your office I couldn't walk a mile around my block without turning back because of the pain and couldn't sleep through the night. I never thought I would ever be able do anything like this again.*

*Thanks so much for giving me my life back!*

### **Ten-Month Follow-up on Knee Stem Cell Injections**

*Before the Regenexx injection, I had extreme difficulty standing and walking on cement for any length of time, plus I experienced a great deal of pain on a daily basis. I did have a lateral release surgery before coming to see you, but I wish today I had never done it as I whole heartedly believe the Regenexx procedure would have reversed the damage all on it own.*

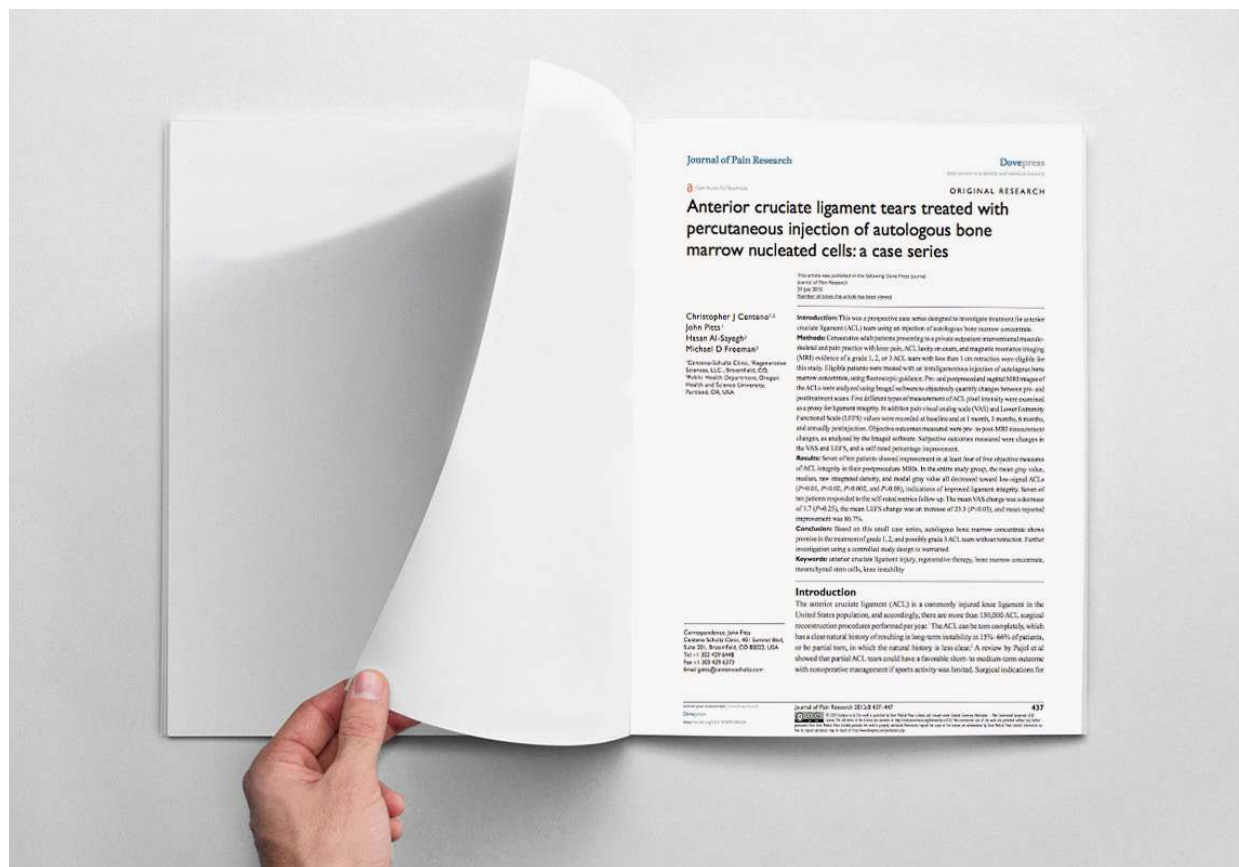*I navigate ships for a living and therefore, deal a lot with vibration and steel decks, both of which stimulate my knee pain. I was afraid until now I would have had to give up my career because of the damage to my knees. I am too young, ambitious and playful to be stopped by bad knees.*

*Within only a couple of weeks following the Regenexx injection to my right knee, I could tell I was experiencing significant improvement. I had only one knee injected, so the comparison was obvious.*

*Regenexx is considered a world leader with the nation's most advanced, non-surgical, stem cell procedures for orthopedic conditions. With over 10 years of experience and tens of thousands procedures performed, we take our work seriously so we can provide you with the most experienced, well researched, and personalized stem cell procedures available today.*

## 2015 Regenexx Paper on ACL

[View the paper here.](#)



## ACL Surgery Alternative: New Regenexx-ACL Video




### Regenexx vs. Other Stem Cell Treatments






## Regenexx Differences



**The Regenexx®**

# Difference


VERSUS OTHER STEM CELL SOLUTIONS



**#1**


THE FIRST ORTHOPEDIC STEM CELL PROCEDURE IN THE U.S. NOW WITH MORE THAN A DECADE OF EXPERIENCE

THE MOST RESEARCHED STEM CELL PROCEDURE FOR ORTHOPEDIC CONDITIONS




**100%**

FOCUSED ON TREATING ORTHOPEDIC CONDITIONS




PUBLISHED PATIENT OUTCOMES & SAFETY DATA





**10 to 20**

TIMES MORE STEM CELLS THAN SIMILAR PROCEDURES (PER UNIT VOLUME)




ALL INJECTIONS AND STEM CELL HARVESTING UTILIZE ADVANCED IMAGING GUIDANCE FOR PRECISION







ALL DOCTORS ARE MUSCULOSKELETAL EXPERTS WITH EXTENSIVE TRAINING IN ORTHOPEDIC INJECTIONS

PROPRIETARY MULTI-INJECTION STEM CELL PROTOCOL FOR THE BEST POSSIBLE OUTCOMES




DEDICATED LAB RESEARCH TEAM FOR CONTINUOUS PROCEDURE IMPROVEMENTS





THE ABILITY TO COUNT CELLS AND DOSE APPROPRIATELY BY CONDITION

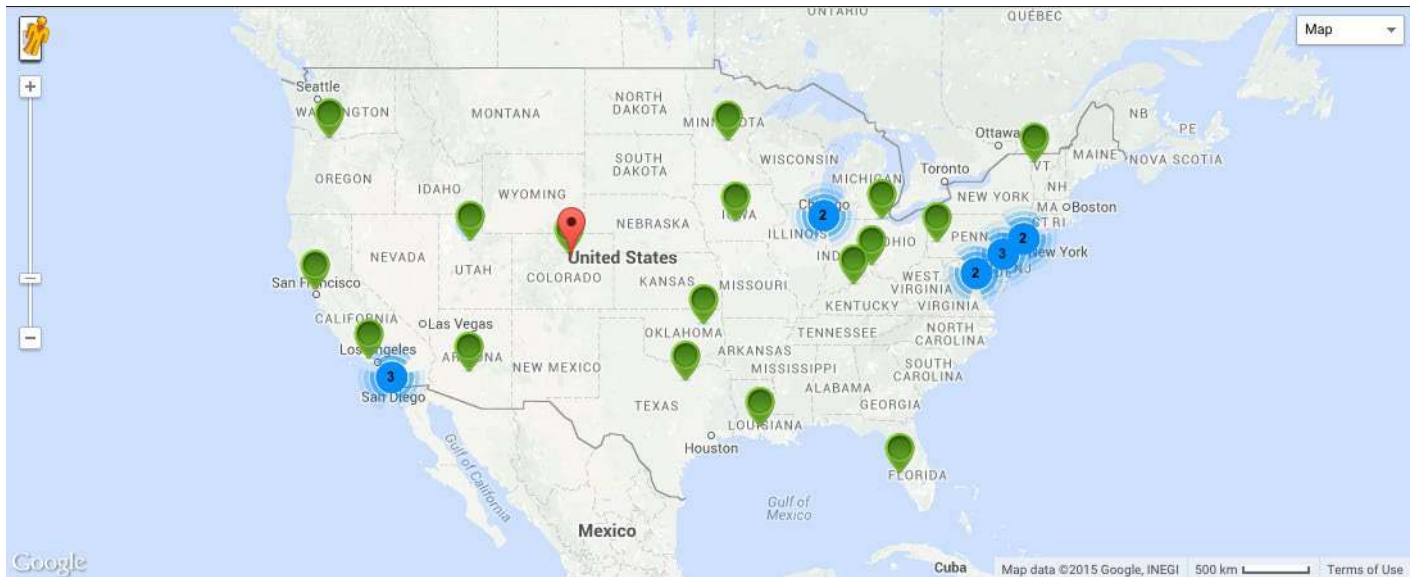

TENS OF THOUSANDS OF PROCEDURE PERFORMED SINCE 2005 • [REGENEXX.COM](http://REGENEXX.COM)

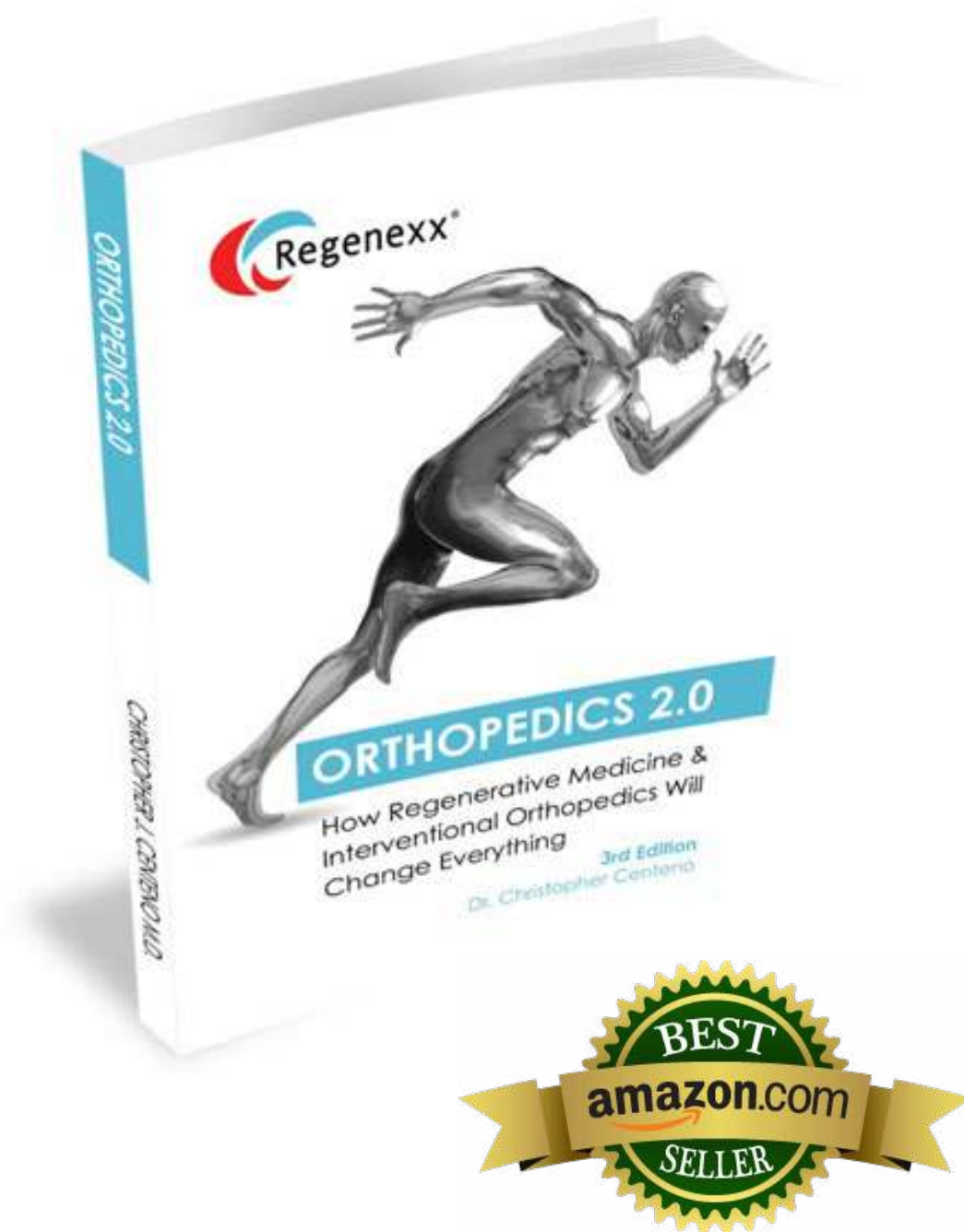


## Regenxx Procedure Network

### Find a Physician

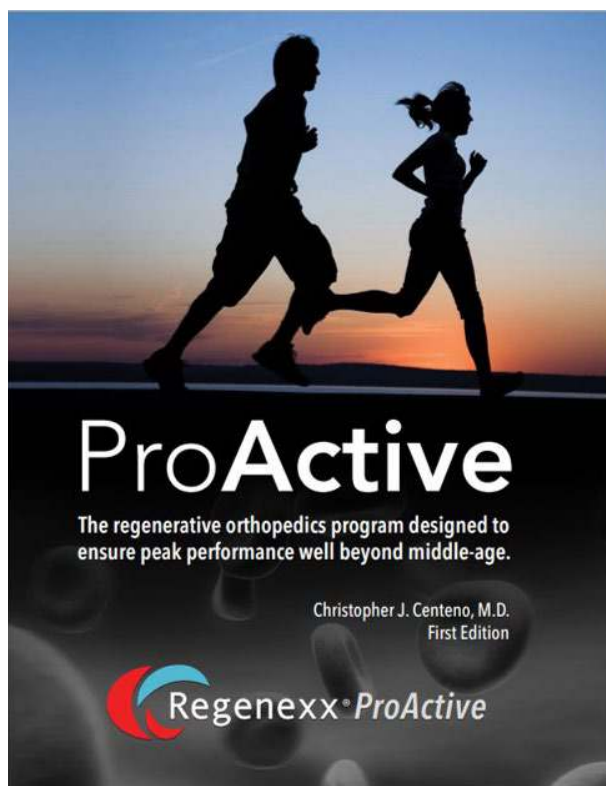


**Free Orthopedics 2.0**- an Amazon Best Seller




## **Regenexx ProActive Book**

[Click to get the book](#)



## **Nutrition 2.0**

[Click to get the book](#)



## Regenexx Advanced Stem Cell Support Formula and Turmeric and Fish Oil Supplements





**[www.regenexx.com](http://www.regenexx.com)**

---

For more information or to schedule  
and appointment call 888-525-3005

---